

# **BASELINE<sup>®</sup>** **EVALUATION INSTRUMENTS**

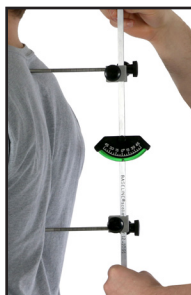## **BASELINE<sup>®</sup> BODY LEVEL / SCOLIOSIS METER**



### **Baseline<sup>®</sup> body level**

Use to determine whether body parts are properly aligned. Ideal for Scoliosis screening.

**How to use:** Hold the Baseline<sup>®</sup> body level with gauge facing you. Extend the moveable arms and place them on two sites. Read the amount of tilt (in degrees) from the scale.



### **Baseline<sup>®</sup> scoliosis meter**

Measurements obtained with scoliosis meter can detect scoliosis and abnormal anteroposterio curve. Use to measure unstable lumbosacral, cervical and thoracic curves. Scale in cm., in. and degrees.

**How to use:** Hold the Baseline<sup>®</sup> scoliosis meter in one hand and loosen the screw on the level with the other hand. Allow the scoliosis meter to turn in your hand, then place the level on the side fastening it with the screw. The lighter markings on the rods are two (2) millimeters apart and the heavier markings are ten (10) millimeters.



Fabrication Enterprises Inc.  
250 Clearbrook Rd, Suite 240  
Elmsford, NY 10523 (USA)  
tel: +1-914-345-9300 • 800-431-2830  
fax: +1-914-345-9800 • 800-634-5370  
FabEnt.com



AJW Technology Consulting GmbH  
Königsallee 106  
40215 Düsseldorf (Germany)

 **WARNING:** Cancer and Reproductive Harm - [www.P65Warnings.ca.gov](http://www.P65Warnings.ca.gov)

## TABLE OF CONTENTS

Introduction.....	page 3
Adam's Sign .....	page 3
How to Measure:	
Shoulder tilt in degrees.....	page 3
Pelvic tilt in degrees.....	page 3
Shoulder tilt in cm/mm .....	page 3
Thoracic deviation in degrees and cm/mm.....	page 4
Normal antero-postero cervical curve - with spine .....	page 4
Normal antero-postero thoracic curve - with spine .....	page 5
Detection of unstable lumbo-sacral angle with spine .....	page 5
School worksheets .....	page 6
Physician's worksheets .....	page 7
More Baseline® evaluation instruments.....	back cover

# BASELINE® SCOLIOSIS METER - PHYSICIANS WORKSHEETS

[illegible]

BASELINE® SCOLIOSIS METER - SCHOOL WORKSHEETS

STUDENT NAME \_\_\_\_\_ ADDRESS \_\_\_\_\_

Date of Examination	Examination Results	Physician Follow-up
5th Grade/Age		
Remarks:		
6th Grade/Age		
Remarks:		
7th Grade/Age		
Remarks:		
8th Grade/Age		
Remarks:		
9th Grade/Age		
Remarks:		
10th Grade/Age		
Remarks:		
11th Grade/Age		
Remarks:		
12th Grade/Age		
Remarks:		

SHOULDER TILT		PELVIC TILT	LUMBAR ROTATIONAL DEVIATION
Degrees	Centimeters/Millimeters (in)		
5th			
6th			
7th			
8th			
9th			
10th			
11th			
12th			
THORACIC DEVIATION IN POSTERIOR RIB CAGE			ANTERIO-POSTERO DEVIATION OF L5-APEX OF SACRUM
Degrees	Centimeters/Millimeters (in)	Centimeters/Millimeters (in)	
5th			Normal = 1.3 cm (5.11 in)
6th			
7th			
8th			
9th			
10th			
11th			
12th			
SPINAL ANALYSIS OF ANTERIO-POSTERO CURVES			
Cervical Curve		Thoracic Curve	
Centimeters/Millimeters (in)		Centimeters/Millimeters (in)	
Normal = 1.3 cm (5.11 in)		Normal = 1.3 cm (5.11 in)	
5th			
6th			
7th			
8th			
9th			
10th			
11th			
12th			

School Nurse

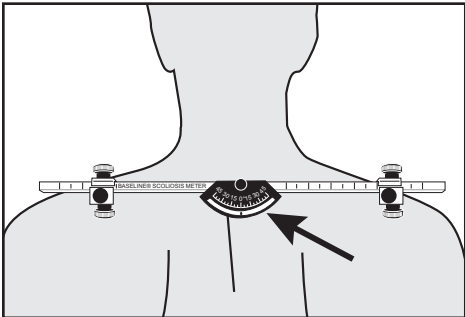
**INTRODUCTION:**

The Baseline® body level and the Baseline® scoliosis meter are used to measure body alignment. The Baseline® body level is excellent for measuring scoliosis (lateral curvature of the spine). The Baseline® scoliosis meter can detect an abnormal anteropostero curve, and measures the unstable lumbosacral, cervical and thoracic curves.

**USER NOTE** Please consult your appropriate training material for more information on testing protocols, procedures and methods. This pamphlet gives a summary of the types of tests that can be performed with the scolioiss meter and body level.

**ADAM’S SIGN** is a standardized neurological / orthopedic procedure and testing method. A patient with scoliosis, when bending over, will have no straightening of the curve. This result is “POSITIVE.” A straightening of the curve indicates a “NEGATIVE” result.

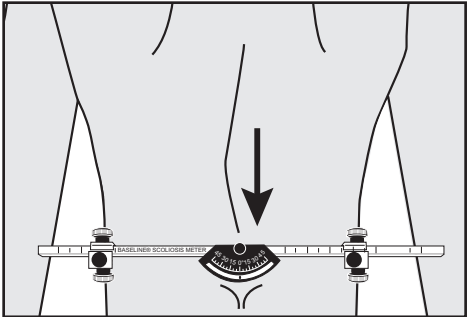
**HOW TO MEASURE:**



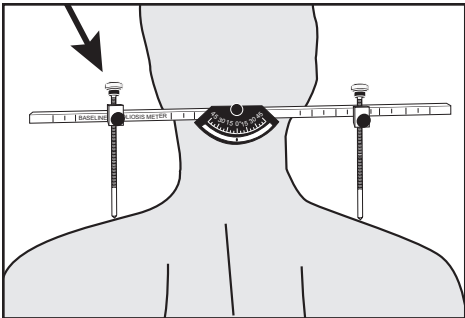
*Shoulder tilt in degrees*

**PELVIC TILT IN DEGREES**

The blocks are released and the rods are placed over the crest of the ilium. The blocks are then pressed firmly toward the midline. Read the angle from the level. If the gauge reads over 2½°, the result is listed as positive.



*Pelvic tilt in degrees*



*Shoulder tilt in centimeters*

**SHOULDER TILT IN DEGREES**

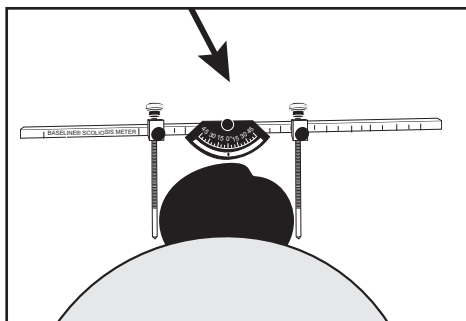
With the patient in a standing position, place the rods on the acromioclavicular articulation. Read the angle from the level gauge. If the gauge reads over 2½°, the reading is listed as positive. NOTE: to read the level gauge and obtain the degree measurement, look for the ball on the gauge.

**SHOULDER TILT IN DISTANCE**

Placing the ends of the rods on the acromioclavicular articulation, you can get the degree measurement. If you release the rod on the higher side and move the bar down until “0” is indicated on the gauge, you will be able to calculate the distance by counting the markings above the block on the high side. This indicates the distance deviation.

## THORACIC DEVIATION IN DEGREES

With the patient bending forward and with the rods locked, place the instrument over the thoracic rib cage with the ends of the rods touching the apex (highest point) of the curve. This point will vary on each individual. In this position you will be able to acquire the degree readings on the gauge by loosening the rod on the high side and pushing the bar down until the gauge reads "0". You will be able to get the distance reading by counting the lines above the block on the high side.



*Thoracic deviation in ribs measured in degrees*

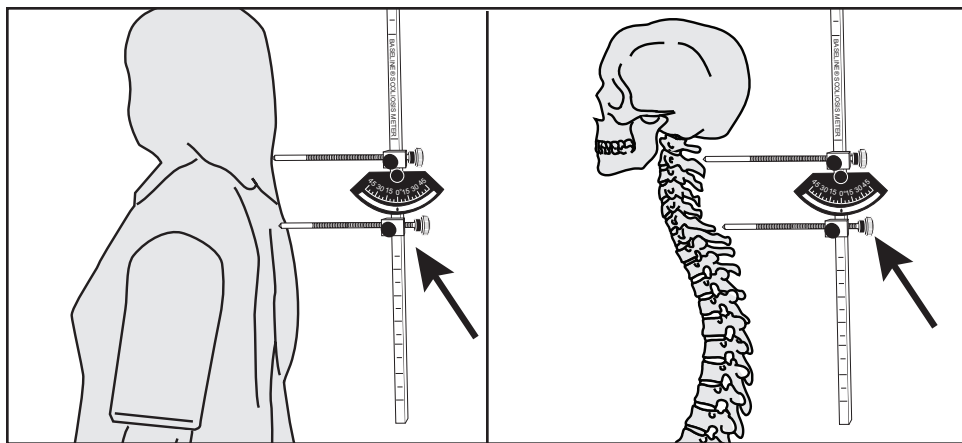
### NOTE:

As above, with the patient in a 90° flexed position, rotation of the lumbar vertebra is measured by bringing the instrument over the lumbar vertebra to the area of the transverse process. The reading will be determined, as demonstrated with thoracic deviation, in degrees, and distance (cm/mm).

**NOTE:** In order to acquire the following readings, it is necessary to have the Base-line® scoliosis meter in a vertical position with the gauge facing the examiner and on 0°.

## CERVICAL CURVE

The top block is positioned so that the rod touches the spinous of C4 (approximately 3-1/4" below the occipital or base of the brain). It is locked in place. The bottom block is positioned so that it touches the spinous process of C7 (most prominent spinous process in the cervical area palpating from the base of the skull downward). It is locked in place. Obtain the distance reading by counting the hash marks. A measurement over 3 cm. indicates lordosis above

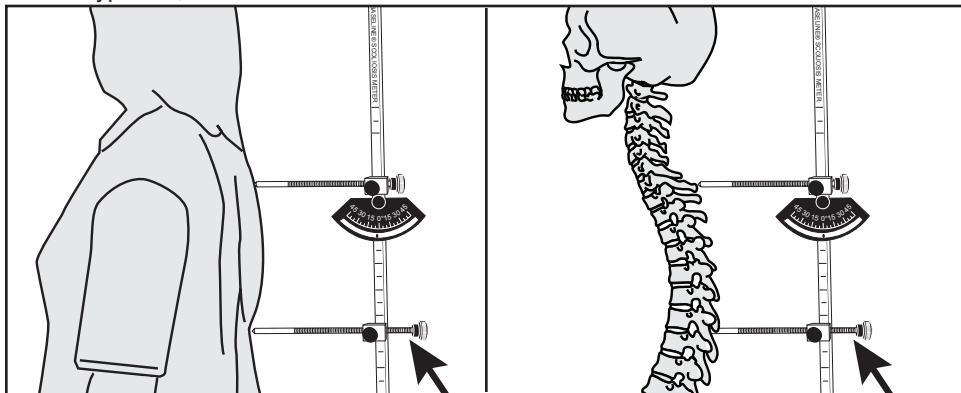


*Cervical curve C4-C7  
Normal = 1-3 cm.*

the normal range and a measurement below 1 cm indicates kyphosis.

## THORACIC CURVE

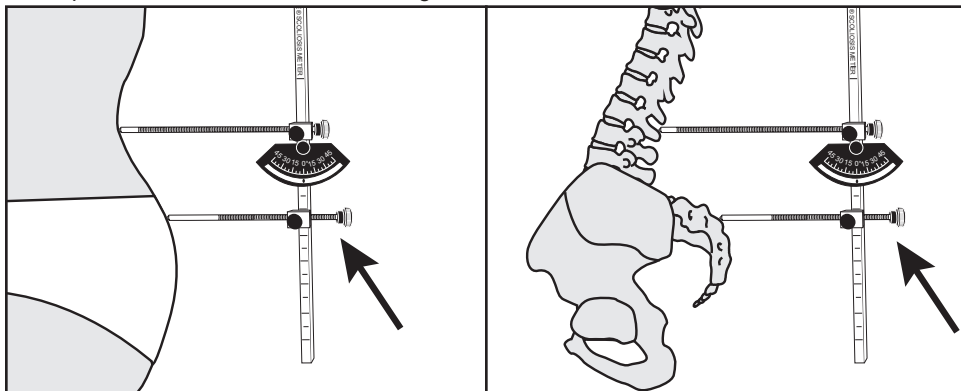
The top block is positioned so that the rod touches the spinous of C7 (most prominent spinous process in the cervical area palpating from the base of the skull downward). It is locked in place. The bottom block is positioned to allow the rod to touch the spinous process of the vertebra which is the apex of the thoracic curve. The bottom rod is loosened and the reading distance reading is possible. The normal range is from 1cm to 4 cm. A decrease in the number indicates a hypo-kyphotic area. An increase in the number indicates a more severe kyphosis, over it's normal 40°.



*Thoracic curve C7 - apex of curve  
Normal = 1-4 cm.*

## ANTEROPOSTERO ANGULATION L5 AND APEX OF SACRUM

The base of the spine is the trigger point of spinal disorders. It is very important that this area undergo the closest scrutiny. Due to all the ramifications in the various severe low back conditions, the top block is positioned so that the rod touches the spinous process of L5 (place your index fingers over the crest of the ilium and then place your thumbs together to locate L5). The bottom block is positioned so that the rod will touch the most prominent tubercle at the apex of the sacrum. The distance reading can then be established. If there is an unstable lumbo-sacral angle, the reading would be greater than 3 cm. If the reading is less than 1 cm, a kyphotic spine would exist. The normal sacral angle is 42°, which would correspond to the 1 to 3 cm normal range.



*anteropostero angulation of L5 and apex of sacrum measured in centimeters/millimeters  
Normal = 1-3 cm.*

**NOTE: The Baseline® scoliosis meter can measure anterior humping by placing rods on the apex of the anterior rib cage to obtain a distance and degree reading.**